



AVIAN FLYER

JUNE 2024

JUNE 2024

YOUR AVIAN FLYER STAFF

CO-EDITORS

Caleb Coblentz
Beth Murphy

CONTRIBUTORS

Caleb Coblentz Beth Murphy
Norma Hoffman
Cynthia Nelson Dan Pitney
Debbie Stout

PUBLISHING AND DISTRIBUTION

Beth Murphy

ARTICLES, ADS AND PHOTOS
ARE WELCOME
AND ENCOURAGED!

IN THIS ISSUE

2024 Officers	Page 2
The Prez Sez	Page 2
Treasurer's Report	Page 3
Canary Band Information	Page 3
Care For Senior Parrots	Page 4
July Picnic Information	Page 9
June Meeting Info	Page 10



Wishing all of our dads a very happy father's day and everyone a fun and safe summer!

Please note that there will be no meeting this month, but our annual picnic will be next month. See all the info about that on page 9 of this issue.

Thank you to everyone for the many prayers for me. My doctor and I both thought that I had perhaps developed hypersensitivity pneumonitis from the birds, as a couple of our members have. The symptoms that I had fit this diagno-

sis and seemed to indicate that. However my health rapidly deteriorated to the point that I had to be taken to the emergency department by ambulance and immediately into a procedure to break up blood clots within my lungs! (My first time in an ambulance as the patient—I retired from being an advanced emergency medical dispatcher.) I nearly died during the procedure and am still recovering. Lesson learned? Keep an open mind when pursuing a diagnosis!

Blood clots and hypersensitivity pneumonitis won't show up on an x-ray. You need a CT scan if you are having symptoms. A while back we featured an article about it in the Flyer. If you would like it repeated contact me at thedovenest@yahoo.com.

I'm sorry for the missed May issue of the Flyer!

Beth Murphy

2024 Officers

President	Dan Pitney	503-866-9524	dspitney@gmail.com
Vice President	Maymelle Wong	503-459-8213	mmwong@easystreet.
Show Chair	Wayne Smith	360-263-3313	wayneandpatti@tds.net
Secretary	Kelly Beaty	541-520-3743	kellylbeaty@icloud.com
Treasurer	Cynthia Nelson	503-246-4041	cynthia.nelson@comcast.net
Board Members	Mary Ann Allen	425-736-0092	maa@allenspace.net
	Quin Ward	425-403-6206	momi.birdz@gmail.com
	Sharon Mrokowski	503-705-0762	minimagicor@hotmail.com
Committees			
Bands:	Norma Hoffmann	360-480-5240	nshoffmann@comcast.net
Membership:	Debbie Stout	406-949-2579	debbiestout@gmail.com
Sunshine:	Nina Rapp	503-663-7277	nina@therapps.net
Newsletter			
Co-Editors:	Caleb Coblentz		caleb.n.coblentz@gmail.com
	Beth Murphy	503-515-5206	thedovenest@yahoo.com
Website			
Coordinator:	Debbie Stout	406-949-2579	debbiestout@gmail.com
Facebook:	Debbie Stout	406-949-2579	debbiestout@gmail.com



THE PREZ SEZ

I hope you are enjoying the beginning of summer and that you and your family are doing well.

Many of you may have heard that our newsletter editor, Beth Murphy, has been quite ill. We are happy that she is improving and able to resume providing our newsletter for us. Thank you, Beth!

I am sorry to cancel our June 8 meeting. I will plan to hold a zoom Board meeting in July and then we will have a short club meeting at our July picnic.

Our club needs of two volunteer positions to be filled. I hope you will consider if you are able to help with either of them. One is the Club Secretary, who keeps minutes of our Club and Board meetings. This position is a member of our Board. The second need is for a Band Secretary. This person orders and distributes canary bands to our club members at the beginning of each year. It does not require a lot of time, but does take some coordination at the time the bands are distributed. Please let me know if you are willing to help out with either of these needs.

Our Columbia Canary Club picnic will be on Saturday, July 20, 12 noon at the Molalla City Park in Molalla, Oregon. Check the newsletter for more information on the park and location. Please bring a salad or main dish to share. Bring your own drinks. The club will provide paper plates and table service, cake and ice cream for dessert. You may also want to bring your own lawn chair. The park has picnic tables. I hope you will plan to come and enjoy our time together at the picnic.

Dan Pitney


May Treasurer's Report

Beginning Checking Account Balance: \$4,980.76
 Beginning CD Balance: \$7,229.41
 Combined Accounts: \$12,210.17

EXPENSES: None

INCOME:
 CD Interest- \$28.68

Ending Checking Account Balance: \$4,980.76
 Ending CD Account: \$7,258.09
 Combined Accounts: \$12,238.85



"Big deal, you can fly. Can you lay an egg?"

CANARY BAND INFORMATION

Hello fellow Columbia Canary Club members,
 I have received our club's 2024 band order for 2,000 CCC bands.

The cost of the bands are 35 cents each. A minimum of 10 bands must be purchased.

Shipping is \$5.00 per order. (If you are paying for orders for two people, please include \$5.00 per person for shipping, since they need to be shipped to different addresses.)

Bands can only be purchased after you have paid your 2024 membership dues.

If you wish, you may pre-order your bands at this time. I will start shipping bands on Tuesday, December 26th.

If you would like to place an order, please email, call or text me at:

nshoffmann@comcast.net (please note the 2 F's and 2N's in my last name.) phone: 360-480-5240

Checks or money orders should be made out to: Columbia Canary Club.

Looking forward to working with you. Wishing everyone a great 2024 breeding season!

Kind regards,


Did you know....
You can be listed on our Breeders page?

All current members may ask to be placed on the BREEDERS page of our website.

www.columbiacanaryclub.org/sales

A text-only listing at the bottom of the page is NO CHARGE.
 A business card ad at the top of the page is \$5 annually.

Questions can be directed to webmaster at dcbbiestout@gmail.com



BABY LOVEBIRDS FOR SALE!!

Club member Roftin Reginald has adorable baby lovebirds for sale, all from their own stock. They have a variety of colors available as well, so if you have been thinking about adding some lovebirds to your aviary now is your chance!! \$90 for one but will negotiate if you buy more! They are located in Portland. Contact her at 971-269-9196 or by email at roftin567@gmail.com.

CARE FOR SENIOR PARROTS

INTRODUCTION

It is a popular belief and a common expectation that larger pet parrots will live to over 50 years of age. However, despite their ability to live much longer than mammals of the same size, most of the captive parrots do not live as long as their wild counterparts. A long-lived bird will ultimately suffer from age-related changes including alterations in behavior, cognitive loss and various health issues such as cardiovascular diseases, cataracts, cancers or metabolic disease. With appropriate care and regular health examinations, it is however possible to delay the effects of aging and to support senior parrots into their old age.

What is a “Senior” Parrot?

When is a pet parrot considered “geriatric”?

The word geriatric refers to old age, especially with regard to healthcare. Of course, this stage of life starts at an age which is specific to each species. It is interesting to realize that reported lifespans of wild psittacine birds are greater than their lifespan in captivity. (Table 1) Indeed, besides the species, life expectancy is also dependant on other factors such as nutrition, genetics, stress and exercise which can greatly influence the aging process.

In avian medicine, a bird is considered geriatric when he reaches the age at which medical conditions associated with aging are being reported. It is a common misconception to consider that longevity records are similar to life-expectancy in parrots, and it is important to acknowledge that most pet psittacine birds will unfortunately not reach 50 years of age.



Table 1. Average life expectancy of commonly kept psittacine species

Species	Median lifespan in the wild (50% of the birds live longer) [years]	Median life expectancy in captivity (50% of the birds live longer) [years]	Longevity record in captivity [years]	Considered geriatric [years]
Budgerigar (<i>Melopsittacus undulatus</i>)	7-15	5.5	18	> 6
Lovebird (<i>Agapornis roseicollis</i>)	5-15	8	25	> 10
Cockatiel (<i>Nymphicus hollandicus</i>)	10-14	9	35	> 12
African grey parrot (<i>Psittacus erithacus</i>)	23	9	48	> 15
Galah (<i>Eolophus roseicapillus</i>)	30	13	73	> 18
White cockatoo (<i>Cacatua alba</i>)	30	12	32	> 20
Blue fronted amazon (<i>Amazona aestiva</i>)	40-49	20	38	> 25
Blue and gold macaw (<i>Ara ararauna</i>)	35-43	21	49	> 30

CARE FOR SENIOR PARROTS

What is aging?

Aging is characterized by the accumulation of changes in organs over the years. This process can ultimately lead to dysfunction of the organ and disease. In other words, old age is not a disease but it can contribute to development of it. The oxidative-damage theory suggests that molecules called reactive oxygen species produced during normal oxidative metabolism lead to molecular changes and age-related decline. Because of their high metabolic rates (high body temperature, high blood-glucose levels, fast heart rate, etc.) the lifetime expenditure of a bird is estimated to be up to 15 times greater than those of mammals. Therefore, accelerated tissue damage and faster aging would be expected in birds. Many species of birds live up to three times longer than mammals of the

same size. It is proposed that birds may actually, age more slowly and gradually because they have developed defensive mechanisms against oxidative damage and a unique capacity for neuro-regeneration.

Nevertheless, even if avian species age slowly, psittacine birds will ultimately become geriatric and suffer from degenerative and neoplastic diseases just as mammals. Such geriatric changes include waning fertility, cardiovascular diseases, cancers, cataracts, hepatic failure, neural aging and osteoarthritis. Aging also affects the immune system, with an associated decrease in immune function and increased sensitivity to infections in older birds.

What are the 6 Most Common Diseases of Senior Parrots?

Atherosclerosis

Cardiovascular disorders are common in psittacine birds as they get older. African grey parrots and Amazon species over 25 years of age, as well as older cockatiels are considered highly sensitive to the development of atherosclerosis. Atherosclerosis is an inflammatory and degenerative condition of the arteries characterized by mineralization and plaque formation in the vascular wall. This disease is more frequent in female birds and in birds with a sedentary lifestyle receiving a high-fat or high-cholesterol diet such as one that is mainly whole seeds. Clinical signs arise because the condition results in a narrowing of the arterial lumen and a resultant decrease in blood flow which may lead to changes in tissue perfusion and even cardiac failure. Less frequently, they can be secondary to thrombosis, hemorrhage, or aneurism. Clinical signs depend on the localization of the lesions and can include sudden death, weakness, difficult breathing, fainting, exercise intolerance, feather picking or stunted feather growth and neurologic signs such as disorientation, blindness, seizures, tremors, clenching of the toes, sudden falls, extension and rigidity of one limb, incoordination and lameness. Diagnosis of atherosclerosis is challenging and can rely on advanced imaging as well as blood analysis. The treatment aims at improving blood flow and slowing progression of the disease. A variety of medical treatments have been advocated to lower cholesterol levels, but none appear to be consistent in their efficacy and a change in diet, as well as exercise, may play an important role in the management of this disease.

Tumors

Tumors (or neoplasms) are abnormal growths which can be benign or malignant (also called "cancers") in nature. Neoplasms have been documented in birds of all ages but, as in any other species, occur most frequently in older individuals. The most common cancers in

psittacine birds involve the skin (e.g. squamous cell carcinomas and fibrosarcoma), the fatty tissue (e.g. liposarcoma), the hematopoietic system (e.g. lymphosarcoma), the cloaca (e.g. carcinoma) and the reproductive tract (e.g. testicular and ovarian neoplasms). However, neoplasms can occasionally affect bones (e.g. osteosarcoma, chondrosarcoma), the liver and other organs. Species such as Galahs are predisposed to develop fatty tumors and budgerigars are commonly affected by renal, reproductive and brain tumors (e.g. pituitary adenoma). Moreover, some viral infections can predispose birds to the development of cancers such as herpesvirus infections (PsHV-1 and PsHV-2) which increase the risk of biliary and cloacal carcinomas. Given the wide variety of organs and cancers, clinical signs can be very diverse and may include lethargy, depression, anorexia, difficult breathing, abdominal swelling, weight loss, incoordination, head tilt, inability to fly, lumps and bumps, non-healing wounds, diarrhea and vomiting, or bleeding. According to the tumor and location, different diagnostics are needed to help identify a cancer and its extension. Blood analysis, diagnostic imaging (radiology, CT-scan, ultrasound), and biopsy or fine needle aspiration of a tissue sample may be needed. Treatment should be adapted to each patient and may include surgical excision, radiation therapy or chemotherapy.

Liver diseases

The functions of the liver as a metabolic and filtering organ make it susceptible to many disorders such as viral infections (e.g. herpesvirus, polyomavirus), bacterial infections (e.g. chlamydiosis), nutritional imbalance (e.g. hepatic lipidosis) or toxicosis (e.g. mycotoxins, pesticides, heavy metal). When such diseases evolve over a span of time, they lead to severe alterations of the liver and can alter its function. This situation is more frequent in older birds and species such as Amazon parrots, cockatiels, macaws and budgerigars. Risk factors include poor diet (all-seed diets,

CARE FOR SENIOR PARROTS

unhealthy table foods), unsanitary food (i.e mold contaminated), and secondary to heart disease. Birds suffering from hepatic insufficiency may show signs such as depression, anorexia, increased thirst, weight loss, overgrown beak and nails, poor feather quality (e.g. lack of powder down, color changes) as well as changes in the droppings (increased urination, discoloration of the urate). Blood analysis, diagnostic imaging and sampling of the liver (fine needle aspirate or biopsy) may help to diagnose hepatic disorders and more specific tests can also be offered (culture and sensitivity, PCR for infectious agents). The prognosis in cases of chronic liver disease is poor. Supportive care can be provided to help with the liver function and include various drugs as well as long-term diet modification. When possible, treatment for the initial disease should be provided.

Cataract

Cataracts are a degenerative eye disorder which shows as opaque areas of the lens. Given that psittacine species can have long life expectancies, idiopathic age-related cataract formation is not uncommon, particularly in macaws after 35 years of age, as well as in older Amazons and cockatiels. Cataracts can also occur secondarily to many causes including trauma, infection, genetics, nutritional deficiency (e.g. zinc, vitamin B2 and B3 or antioxidants such as vitamin A and E) or certain light exposure. If the onset of cataracts is gradual, adaptation to decreased vision usually occurs and the disease may be unnoticed. Cataracts can eventually lead to total vision loss which can result in inactivity, reluctance to move, reduction in appetite and interaction with other birds and people. In some birds, blindness can lead to fearful behaviors such as startling, screaming or biting. Birds with unilateral blindness tend to hold their heads to the side so that their visual eye faces forward. Complications of cataracts can include retinal detachment and lens-induced (or phacolytic) uveitis which is an inflammation of the iris secondary to the breakdown of the lens. Treatments in case of cataracts aim at improving the quality of life and can rely on ocular drops but some larger birds may be candidates for a surgery called phacoemulsification.

Osteoarthritis

Osteoarthritis is also called degenerative joint disease and is caused by abnormal wearing of the cartilage that covers and cushions the joints. It is more common in psittacine birds over 15 years of age and these lesions can occur at an earlier age in situations where there is normal wear on abnormal joints (e.g. birds that experienced trauma, or suffer from metabolic bone disease) or abnormal wear on normal joints (e.g. obesity, sedentarity). Commonly affected joints include the phalangeal joints of the feet, the tarsus and the stifle, whereas the joints of the wings seem less frequently affected. Occasionally, osteoarthritis can lead to complications such as bumblefoot, ulcerative dermatitis and



This aging parrot suffers from cataracts. - note the opaque area on the lens.

callous formation. Osteoarthritis is mainly responsible for pain. Birds with osteoarthritis often present with lameness, decreased activity, increased sleeping time, decreased alertness, behavior changes (including increased irritability or vocalization), falling off perches, stiff or sore joints, feather picking or mutilation, as well as reluctance to fly, jump or climb. Clinical signs and radiographs can help to diagnose osteoarthritis. Treatments are focused on slowing progression of the disease and relieving pain. Environmental adaptations may be considered to help disabled birds.

Senility

As in mammals, the cellular activities of parrots produce molecules (reactive oxygen species) that are potentially dangerous. Antioxidants normally help to protect the brain against their deleterious effects. However, with aging, fewer antioxidants are produced which allows these reactive oxygen species to damage neurons. Although effects of aging on bird cognition are unknown, conserved mechanisms underlie age-related changes in the avian brain similar to those observed in mammals. Moreover, some studies have noted that the volume of the hippocampus, which is responsible for certain types of memory, is reduced in captive birds, with an associated decrease in particular types of memory. Anecdotal accounts from veterinarians and owners of older birds suggest that senility may occur and can be evidenced by inability to locate entrances to cages and food sources, with which they were previously familiar, as well as behavioral changes and altered interactions with human and avian cohabitants.

CARE FOR SENIOR PARROTS

How to Improve Health of Older Birds

Senior birds have specific needs and require increased attention, including more frequent visits to the veterinarian, possible changes in diet, and in some cases modifications to their home environment. Following are some basic considerations when caring for older psittacine birds.

Exercise

As with older people, keeping older birds active through appropriate exercise will be beneficial to prevent development of atherosclerosis or osteoarthritis. Flighted birds can be allowed or encouraged to fly. Flapping exercises can also be done by gently raising and lowering the bird, or walking swiftly with them while allowing them to perch on a hand or arm. When this is not possible, birds should be stimulated to climb and walk. For example, it is possible to ask them to “step up” several times as part of their exercise routine. In birds suffering from stiff joints, passive motion exercises can be performed. One example of a passive motion exercise is allowing the bird to perch on its owner while gently rocking in a chair. Finally, foraging for food is another way that can be used to encourage exercise, by putting foraging boxes on different sides of the cage or enclosure.

Diet

There is overall little to no research on the nutritional needs of the geriatric psittacine bird. However, it is believed that diets should be easily digested and contain reduced levels of proteins, energy, phosphorous, sodium and of some minerals and vitamins compared to those received earlier in life. However, increases in vitamins A, E, B12, thiamine, pyridoxine, zinc, lysine, linoleic acid and other omega 3 and 6 fatty acids may be helpful in overcoming some of the metabolic and digestive changes seen in old age.

Low-fat formulated diets with antioxidant fresh vegetables and fruits will provide the necessary nutrients to the geriatric bird and limits development of atherosclerosis or other degenerative changes in the brain and liver. A healthy diet rich in omega-3 and -6 fatty acids may help to slow down the degenerative process such as cataracts, osteoarthritis and atherosclerosis in geriatric parrots. Moreover, essential fatty acids (flaxseed oil, walnuts, and almonds), have been used to reduce inflammation and have renal protective effects. Reduction in fat and cholesterol in the diet may help to prevent atherosclerosis and liver disease. Zinc, selenium and some vitamins (C, E and riboflavin) are considered important in the prevention of cataracts. Vitamin A will support the immune system and reduce the risk of respiratory infections.



CARE FOR SENIOR PARROTS

Enrichment

Stimulating older psittacine birds through social interactions can help keep them mentally active and slow down senility. Perch diameter, texture, or padded perches can all help birds with weak or painful legs or feet and help to decrease the development of bumblefoot in birds with osteoarthritis. Moreover, in birds suffering from decreased vision, minimal alteration of the home environment is critical specially as far as perching, food and water bowls are concerned since it will help the bird maneuver and access nutritional resources safely. Foraging opportunities can also entertain and distract the bird and diminishing feather picking or mutilation behaviors.

Regular health checks

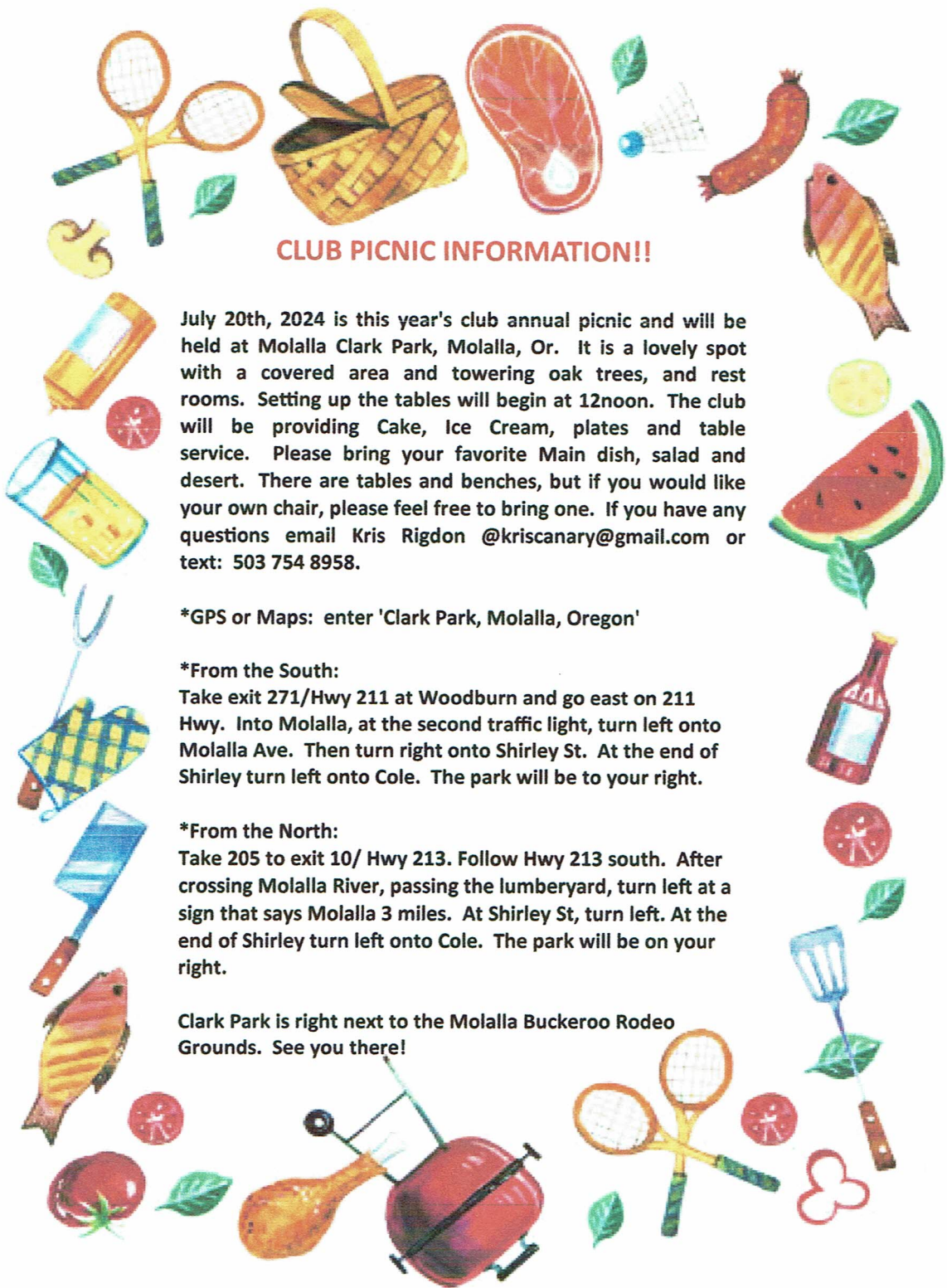
Prevention of many of the geriatric problems lies in early recognition of risk factors and diseases. Annual health checks allow your veterinarian to identify early signs of diseases and provide you advices to reduce risk factors that could lead to them. When a bird is geriatric, check-ups should be semi-annual to detect and treat any problem as early as possible. Senior bird exams are similar to those for younger birds but are generally more in-depth and may include specific evaluations for diseases that are more likely in older psittacine. Additionally, diagnostics might be recommended to check organ function (blood analysis, stool analysis, cardiac ultrasound, etc.), or to investigate any abnormalities noticed during physical examination.

Before any medical signs become apparent, behavioral changes can serve as important indicators that something is changing in an older pet, which may be due to medical or other reasons. If any changes in your bird's behavior are noticed, such as water consumption, droppings appearance, eating habits or preening habits, please consult your veterinarian.

Conclusion

Nutrition, exercise and genetics can all influence the life expectancy of parrots. Improved education of veterinarians and increased awareness of specific needs of parrots have led to better healthcare and increased life expectancy. However, your role as a primary caretaker is invaluable in preventing some of the more frequent diseases encountered in geriatric psittacine birds: nutrition, habitat, social interaction, and exercise are all of critical importance to limit disorders of advanced age. Your veterinarian can assist you in evaluating quality of life of your pet bird and will be able to compare to previous years if regular check-ups are performed. On some occasions, husbandry and medical changes are just not enough to improve the quality of life to an acceptable level. In such cases, your veterinarian will be able to assist you with end of life decisions.





CLUB PICNIC INFORMATION!!

July 20th, 2024 is this year's club annual picnic and will be held at Molalla Clark Park, Molalla, Or. It is a lovely spot with a covered area and towering oak trees, and rest rooms. Setting up the tables will begin at 12noon. The club will be providing Cake, Ice Cream, plates and table service. Please bring your favorite Main dish, salad and desert. There are tables and benches, but if you would like your own chair, please feel free to bring one. If you have any questions email Kris Rigdon @kriscanary@gmail.com or text: 503 754 8958.

*GPS or Maps: enter 'Clark Park, Molalla, Oregon'

***From the South:**

Take exit 271/Hwy 211 at Woodburn and go east on 211 Hwy. Into Molalla, at the second traffic light, turn left onto Molalla Ave. Then turn right onto Shirley St. At the end of Shirley turn left onto Cole. The park will be to your right.

***From the North:**

Take 205 to exit 10/ Hwy 213. Follow Hwy 213 south. After crossing Molalla River, passing the lumberyard, turn left at a sign that says Molalla 3 miles. At Shirley St, turn left. At the end of Shirley turn left onto Cole. The park will be on your right.

Clark Park is right next to the Molalla Buckeroo Rodeo Grounds. See you there!

JUNE MEETINGS

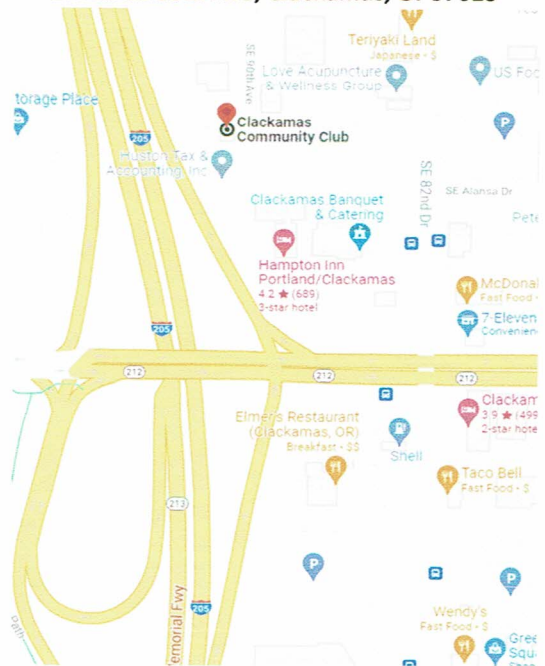
PLEASE NOTE: There will be no meetings this month. Check page 9 for information about the annual picnic in July! Happy Summer!

DIRECTIONS TO CLACKAMAS COMMUNITY CLUB

FROM THE SOUTH: I-205 North to Exit 12 for OR-212 E toward OR-224 E/Damascus/Estacada. Use middle lane to turn right onto OR-212 E. Turn left at the 1st cross street onto SE 82nd Drive. Turn left onto SE St. Helens Street. Turn left onto SE 90th Avenue. Destination will be on the left after a right hand curve. Smaller of the two buildings. (Was once a residence.)

FROM THE NORTH: I-205 South. Take exit 12A to merge onto OR-212 E toward Damascus. Merge onto OR -212 E. Turn left on 82nd Drive. Turn left onto SE St. Helens Street. Turn left onto SE 90th Avenue. Destination will be on the left after a right hand curve. Smaller of the two buildings. (Was once a residence.)

CLACKAMAS COMMUNITY CLUB MAP
15711 SE 90th Ave, Clackamas, Or 97015



Columbia Canary Club
P.O. Box 2013
Clackamas, OR 97015

